

CONGENITAL ANOMALIES OF THE KIDNEY AND URINARY TRACT (CAKUT)

Nadica Ristoska-Bojkovska

Clinical Hospital Acibadem Sistina Skopje, Macedonia

Address for correspondence: Nadica Ristoska Bojkovska, MD, PhD
– Clinical Hospital Acibadem Sistina, Skupi 5a , 1000 Skopje, Macedonia
Tel.+389 2 3 099 741; Mobile+ 389 70 807 736; E-mail: nadicarbojk@yahoo.com

ABSTRACT

Congenital anomalies of the kidneys and urinary tract (CAKUT) are found in 3-6 out of 1.000 of the newborns, or according to some statistics they are represented in 0.5% of all pregnancies. Congenital abnormalities of the kidneys and urinary tract present a family of diseases of various anatomic spectrum, including renal anomalies, and anomalies of the bladder and urethra. The study was retrospective-prospective which means that it included newly diagnosed patients suffering from CAKUT, as well as those patients with already diagnosed and well defined CAKUT on the basis of imaging studies which have been processed according to the protocol for this study.

Key words: Congenital anomalies, kidney, urinary tract, familial screening, outcome.

INTRODUCTION

This paper is motivated by the awareness that so far, in Macedonia there has not been major or serious studies prepared in relation to congenital kidney and urinary tract anomalies. The standard techniques used to examine the kidneys and the urinary tract are: echosonography examination, intravenous pyelography, micturition cystography, diuretic scintigraphy, cortical scintigraphy (Tc-99 DMSA scan), direct radionuclear cystography, and in selected cases computerized tomography and nuclear magnetic resonance.

Factors for development of CAKUT. The first factor is the obstruction of the lower urinary tract in the fetal kidney. If the obstruction is present in the early stadium of the renal morphogenesis at a high degree, the kidney will be dysplastic or aplastic. All these structural modifications might be result of genetic modifications, yet, little is known of the molecular pathogenesis of these anomalies (1).

The second group of factors are the abnormalities caused by genes in the kidney developing (2,3).

The third factor are the substances such as medicines or environmental factors, which are transmitted from the mother to the fetus through the placenta and affect the development of the fetal kidney. Most common substances are those having inhibitory effect of renin-angiotensin- aldosterone system (4,5).

The aim of this study was to analyze the clinical, genetic and prognostic aspects of the congenital anomaly of the kidneys and the urinary tract (CAKUT) in a series of 749 pediatric patients diagnosed at the Pediatric Clinic in the period from 2010 until 2015.

METHODS

Echosonography is widely used for diagnostics of certain organs and organ systems. Ultrasonography is used for early detection of renal agenesis, renal hypodysplasia, multicystic kidneys, diagnosis of the urinary tract obstruction. It is possible to evaluate the size of the kidney, position, anatomy, anomalies, volume and function of the bladder.

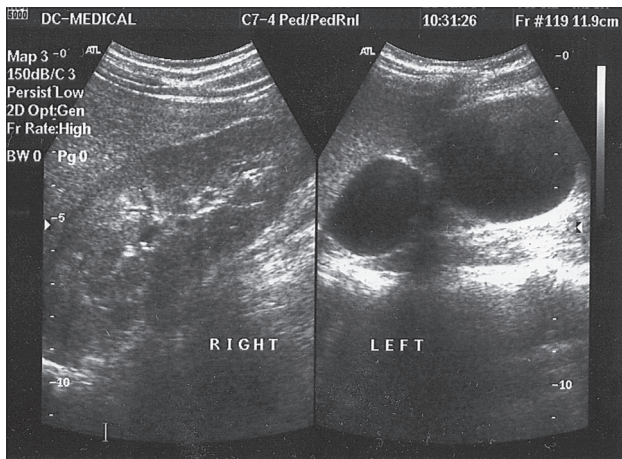


Figure 1. Left cystic dysplastic kidney

Echasonography examination is necessary in all newborns in which a bilateral serious fetal hydronephrosis is prenatally detected (6,7).

Radiological investigations: Voiding cystourethrography is an examination method by which after retrograde introducing of a contrast agent into the bladder, screening is done during micturition. Voiding cystourethrography is most often done in children suffering from urinary infections in order to confirm or exclude the existence of a vesicoureteral reflux (8).

Radioisotope investigations

^{99m}Tc - Dimercaptosuccinic acid (DMSA) renal scintigraphy

DMSA is an investigation which shows the size, shape and position of a functional renal parenchyma. The lack of a radioisotope in the normal renal position means a diagnosis of a multicystic renal dysplasia or renal agenesis, or in certain cases a unilateral renal hypoplasia.

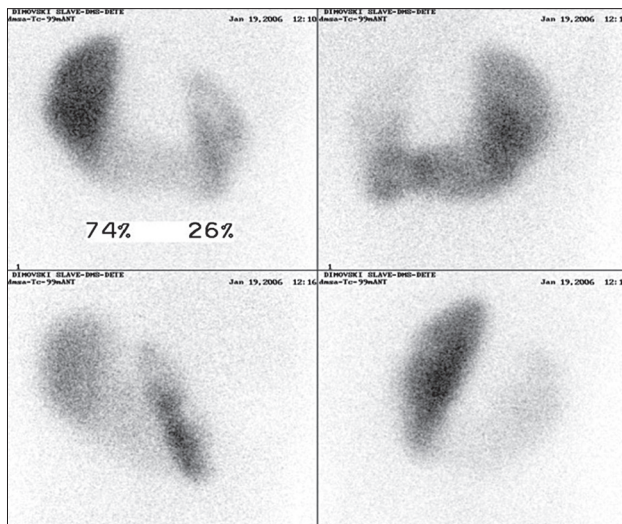


Figure 3. Tc^{99m} DMSA scan shows arcuate kidney

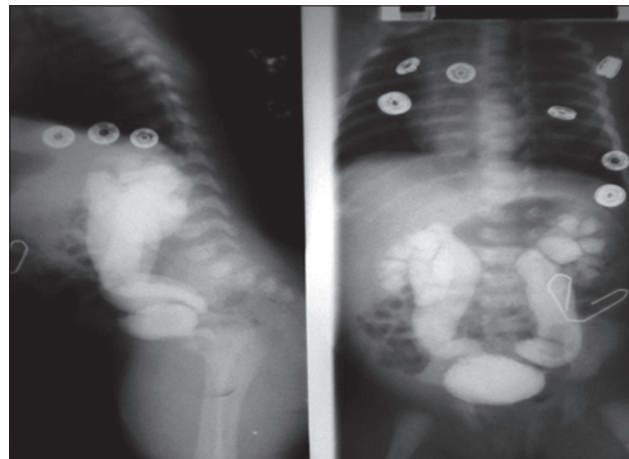


Figure 2. Bilateral severe vesicoureteral reflux

^{99m}Tc - Diethylenetriamine pentaacetic acid (DTPA) renoscintigraphy

DTPA is a noninvasive method for differentiation between a hydronephrosis and hydrouretero-nephrosis of obstructive type where a surgical correction is needed.

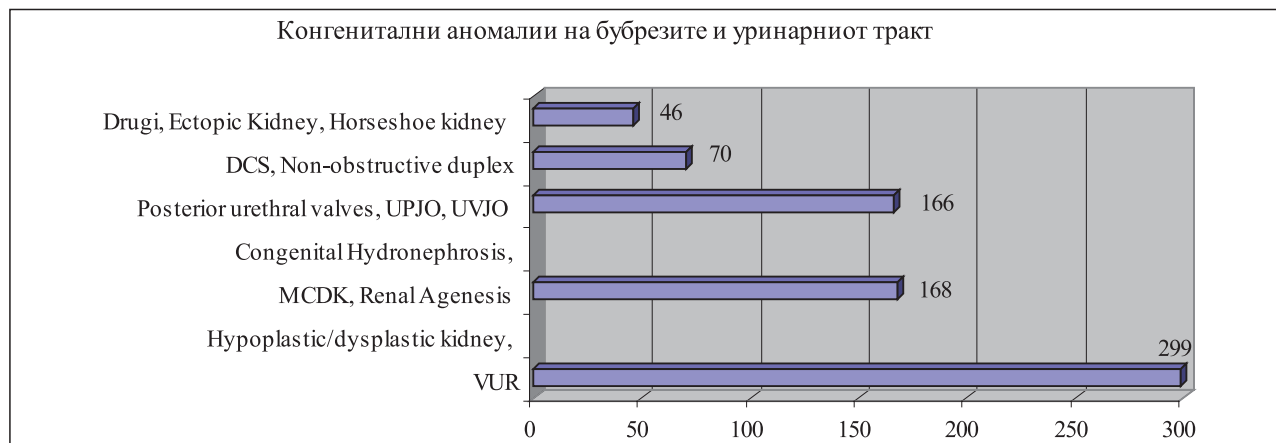
MR Urography (magnetic resonance urography). MR urography is performed with application over gadopentetate dimeglumine – DTPA. MRU is effective in investigation of pediatric uropathological conditions and in the investigating of the congenital anomalies. It provides morphological and functional information (9).

RESULTS

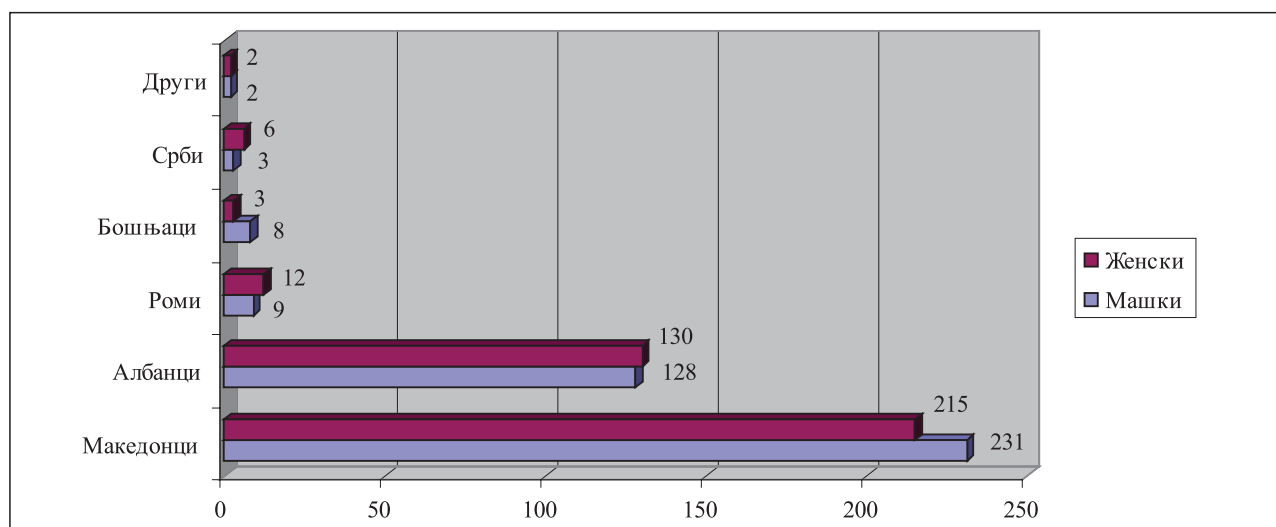
In our series 25% of CAKUT has been detected by prenatal ultrasound screening.

A positive familial history has been found in 12.42% of the patients where no significant statistical difference has been identified in relation to the ethnicity and the type of the malformation. The most common malformation in our series is vesicoureteral reflux (VUR – 39.92%).

- in the whole series of patients, 1/4 of the children had extra renal malformations (in other organs),
- they were least present in children with VUR (16.7%),
- they were most present in children with ectopic kidney and fusion (43.4%),
- ultrasound familial screening was performed in 620 index patients, where a total of 1,614 relatives were tested,
- totally detected families with CAKUT make 10.9%,



(Congenital anomalies of the kidneys and the urinary tract)



(Other–Serbs–Bosniaks–Roma–Albanians–Macedonians) (Male – Female)

- the follow-up of the patients of our series lasted 5-6 years, where the terminal uremia was achieved in 2.1% of the patients.

CONCLUSION

In general, we can conclude that the prognosis of the pediatric CAKUT in Macedonia is excellent. Adverse prognosis is associated with the existence of obstructive anomalies (valvula of the posterior urethra), and bilateral affection (hypo dysplasia, VUR). The favorable results obtained from this study are due to the high non-selectiveness of our series.

With this study we created a database of patients with syndromic and non-syndromic CAKUT, we identified an unambiguous existence of the genetic factor through the familial ultrasound screening and the existence of extra renal abnormalities, thus enabling participation in future multicentric studies.

REFERENCES

- Vlad M., Ionescu N., Ispas A.T., Ungureanu E., Stoica C., Morphological study of congenital megaureter. Romanian Journal of morphology and embryology 2007; 48 (4): 381 - 390.
- Sanna-Cherchi S., Caridi G., Weng P.L., Scolaro F., Perfumo F., Gharavi A.G., Ghiggeri G.M., Genetic approaches to human renal agenesis/hypoplasia and dysplasia. *Pediatr. Nephrol.* 2007; 22: 1675 – 1685
- Woolf A.S.: Unilateral multicystic dysplastic kidney. *Kidney Int.* 2006; 69: pp. 190 – 193.
- Brennan K.A., Kaufman S., Reynolds S.W. et al., Differential effects of maternal nutrient restriction through pregnancy on kidney development and later blood pressure control in the resulting offspring. *Am. J. Physiol. Regul. Integr. Comp. Physiol.* 2008; 295: 197 - 205.

5. Sekine T., Miura K., Takahashi K., Igarashi T. Children's toxicology from bench to bed - Drug - induced renal injury (1): The toxic effects of ARB/ACEI on fetal kidney development. *The Journal of Toxicological Sciences*. 2009; 34 (2): 245 - 250.
6. Tsuchiya M., Hayashida M., Yanagihara T. et al. Ultrasound screening for renal and urinary tract anomalies in healthy infants. *Pediatrics Int*. 2003; 45: 617 - 623.
7. Hindryckx A., De Catte L., Prenatal diagnosis of congenital renal and urinary tract malformations. *Facts Views Vis. Obgyn*. 2011; 3 (3): 165 - 174
8. Renkema K.Y., Winyard P.J., Skovorodkin I.N., Levtchenko E., Novel perspectives for investigating congenital anomalies of the kidney and urinary tract (CAKUT). *Nephrol. Dial. Transpl*. 2011; 26 (12): 3843 - 3851.
9. Rohrschneider W.K., Haufe S., Tonshoff B., Wunsch R., Darge K., Clorius J., Troger J., Functional and morphologic evaluation of congenital urinary tract dilatation by using combined static-dynamic MR urography: findings in kidneys with a single collecting system. *Radiology* 2001; 224: 683 - 694.

Резиме

ВРОДЕНИ АНОМАЛИИ НА БУБРЕЗИТЕ И НА УРИНАРНИОТ ТРАКТ (САКУТ)

Надица Ристоска-Бојковска

Клиничка болница Ацибадем Систина Скопје, Македонија

Апстракт

Конгениталните аномалии на бубрезите и на уринарниот тракт (САКУТ) се присутни кај 3–6 од 1000 новородени или, според некои статистики, присутни се кај 0,5% од сите бремености. Конгениталните абнормалности на бубрезите и на уринарниот тракт претставуваат фамилија заболувања со различен анатомски спектрум, вклучувајќи ги аномалиите на бубрегот, аномалиите на бешиката и на уретрата. Студијата беше ретроспективно-проспективна, што значи дека беа вклучени новодијагностицирани пациенти со САКУТ, како и оние пациенти кај кои е веќе дијагностициран и добро дефиниран САКУТ врз база на имиџинг-студии и тие се обработени по протоколот за оваа студија.

Клучни зборови: конгенитални аномалии, бубрези, уринарен тракт, фамилијарен скрининг, исход